



PATIENT

Wilson LeBlanc

SPECIES

Canine

BREED

Pointer

SEX

Male Neutered

AGE

7/21/2016

WEIGHT

33 kg

INTERPRETED BY

Andrea Nicastrò DVM
Diplomate ACVIM
(Sm Animal Internal Med)

**IMAGING
PERFORMED BY**

Andrea Nicastrò DVM
Diplomate ACVIM
(Sm Animal Internal Med)

HOSPITAL NAME

Amber Leavis

REFERRING VET

VCA Palmetto

INVOICE

22815

DATE

4-3-26

PRESENTING CLINICAL SIGNS

Clinical Exam Findings: Initially presented in January for persistent diarrhea. Rectal exam revealed prostatomegaly at that time and bloodwork and urine sent out showed leukocytosis and leukocytes with blood in urine but no bacteria. Patient was placed on Marbofloxacin and Carprofen, which improved P's clinical signs until medication finished. Antibiotics have been repeated and continued for 4 weeks and signs improve until it finishes. Rectal exam on 3/31 shows improved size of prostate. P has not been placed back on antibiotics at this time. AUS is to assess prostate to determine if infection/BPH/neoplasia.

Abnormal lab-work values: Will be emailed

ULTRASONOGRAPHIC EXAMINATION OF THE ABDOMEN

Urinary System

The urinary bladder wall is normal in thickness. The mucosal surface in the region of the apex is slightly irregular. Luminal contents are mostly anechoic. The bladder is moderately distended. Luminal contents are anechoic. No cystic calculi are observed. The region of the trigone and the proximal urethra, visible to a depth of 2 cm, are normal.

The prostate is enlarged (3.20 cm in width x 4.18 cm in length) and with slightly irregular peripheral contours. The parenchyma is hypoechoic relative to surrounding omental fat and slightly mottled in appearance. Surrounding mesentery is hyperechoic. The prostatic urethra appears normal without evidence of dilation or obstruction.

The left kidney is normal in size (6.72 cm in length) with a normal shape, architecture and smooth peripheral margins. There is a normal 1:3 cortex to medulla ratio with normal corticomedullary distinction. There is no evidence of pyelectasia, nephroliths, infarcts or hydronephrosis. Renal vasculature is normal.

The right kidney is normal in size (6.80 cm in length) with a normal shape, architecture and smooth peripheral margins. There is a normal 1:3 cortex to medulla ratio with minimal- to mild loss of corticomedullary distinction. There is no evidence of pyelectasia, nephroliths, infarcts or hydronephrosis. Renal vasculature is normal.

Adrenal Glands

The left adrenal gland is normal in size (0.70 cm at cranial pole) (0.64 cm at caudal pole) with a normal shape and homogenous parenchyma. The glandular echogenicity and detail are unremarkable. Capsule, cortex, and medullary definition are normal. The phrenicoabdominal vein and surrounding vasculature are normal.

The right adrenal gland is normal in size (1.05 cm at cranial pole) (0.72 cm at caudal pole) with a normal shape and homogenous parenchyma. The glandular echogenicity and detail are unremarkable. Capsule, cortex, and medullary definition are normal. The phrenicoabdominal vein and surrounding vasculature are normal.

Spleen

The spleen is subjectively normal-in-size with a normal capsular contour. There is appropriate echogenicity and echotexture. No focal lesions are observed. Splenic vasculature is normal.

Liver

The liver is normal- to slightly prominent-in-size with smooth peripheral contours. The parenchyma is isoechoic relative to the spleen and diffusely homogeneous in appearance. No distinct focal lesions are observed. Vascular and biliary tracts are of normal volume with no evidence of congestion. The portal vein to caudal vena cava ratio is approximately 1: 1.



PATIENT

Wilson LeBlanc

The gallbladder lumen is moderately distended. The wall is thin and smooth. A small- to moderate amount of echogenic- to mineralized debris/sand is observed within the lumen. The cystic and common bile ducts are normal/not seen.

SPECIES

Canine

Gastrointestinal

The gastric lumen is not distended. The gastric wall and pylorus are normal in thickness with a normal layering pattern. The pyloric outflow tract is patent. The small intestinal lumen is not dilated. The small intestinal wall is normal in thickness with a normal layering pattern and appropriate mural detail. Discreet masses are not identified. The ileoceocolic junction and colonic wall are normal. There is no evidence of an obstructive pattern.

BREED

Pointer

Pancreas

The right limb is prominent-in-size, with slightly irregular peripheral contours. The parenchyma is heterogenous in appearance, with ill-defined hypochoic areas. The pancreatic duct is not overtly dilated.

SEX

Male Neutered

Lymph Nodes

A 2.61 x 0.77 cm medial iliac lymph node is visualized.

AGE

7/21/2016

Free Abdomen

There is no obvious evidence of free fluid.

WEIGHT

33 kg

Other

A brief echocardiogram reveals no evidence of pericardial effusion or obvious right atrial/auricular mass.

INTERPRETED BY

Andrea Nicastrò DVM
Diplomate ACVIM
(Sm Animal Internal Med)

ULTRASONOGRAPHIC FINDINGS

Primary Findings

- Prostatomegaly/mass effect. Neoplasia (i.e., prostatic adenocarcinoma, transitional cell carcinoma) is suspected, with a lower possibility of prostatitis or prostatic hyperplasia. Mild adjacent retroperitonitis is present.
- The prominent medial iliac lymph node may be reactive. However, early metastatic disease cannot be excluded.

IMAGING

PERFORMED BY

Andrea Nicastrò DVM
Diplomate ACVIM
(Sm Animal Internal Med)

Secondary Findings

- Mild, bilateral nonspecific age-related renal changes
- The diffuse hepatic changes are most consistent with vacuolar hepatopathy (i.e., endocrine, idiopathic) with a lower possibility of inflammatory disease, infiltrative neoplasia, or other hepatopathy.
- Gallbladder debris/sand, non-mucocele
- The pancreatic changes are most consistent with age-related parenchymal remodeling, potentially secondary to a prior inflammatory episode, early fibrosis or chronic pancreatitis.

HOSPITAL NAME

Amber Leavis

REFERRING VET

VCA Palmetto

INVOICE

22815

INTERPRETATION OF THE FINDINGS & FURTHER RECOMMENDATIONS

DATE

4-3-26

- Three-view thoracic radiographs are recommended to assess for pulmonary metastases.
- A urine BRAF test is recommended to further evaluate for prostatic neoplasia.
- Depending on the results, consultation with a board-certified oncologist may be indicated.



PATIENT

Wilson LeBlanc

SPECIES

Canine

BREED

Pointer

SEX

Male Neutered

AGE

7/21/2016

WEIGHT

33 kg

INTERPRETED BY

Andrea Nicastrò DVM
 Diplomate ACVIM
 (Sm Animal Internal Med)

IMAGING PERFORMED BY

Andrea Nicastrò DVM
 Diplomate ACVIM
 (Sm Animal Internal Med)

HOSPITAL NAME

Amber Leavis

REFERRING VET

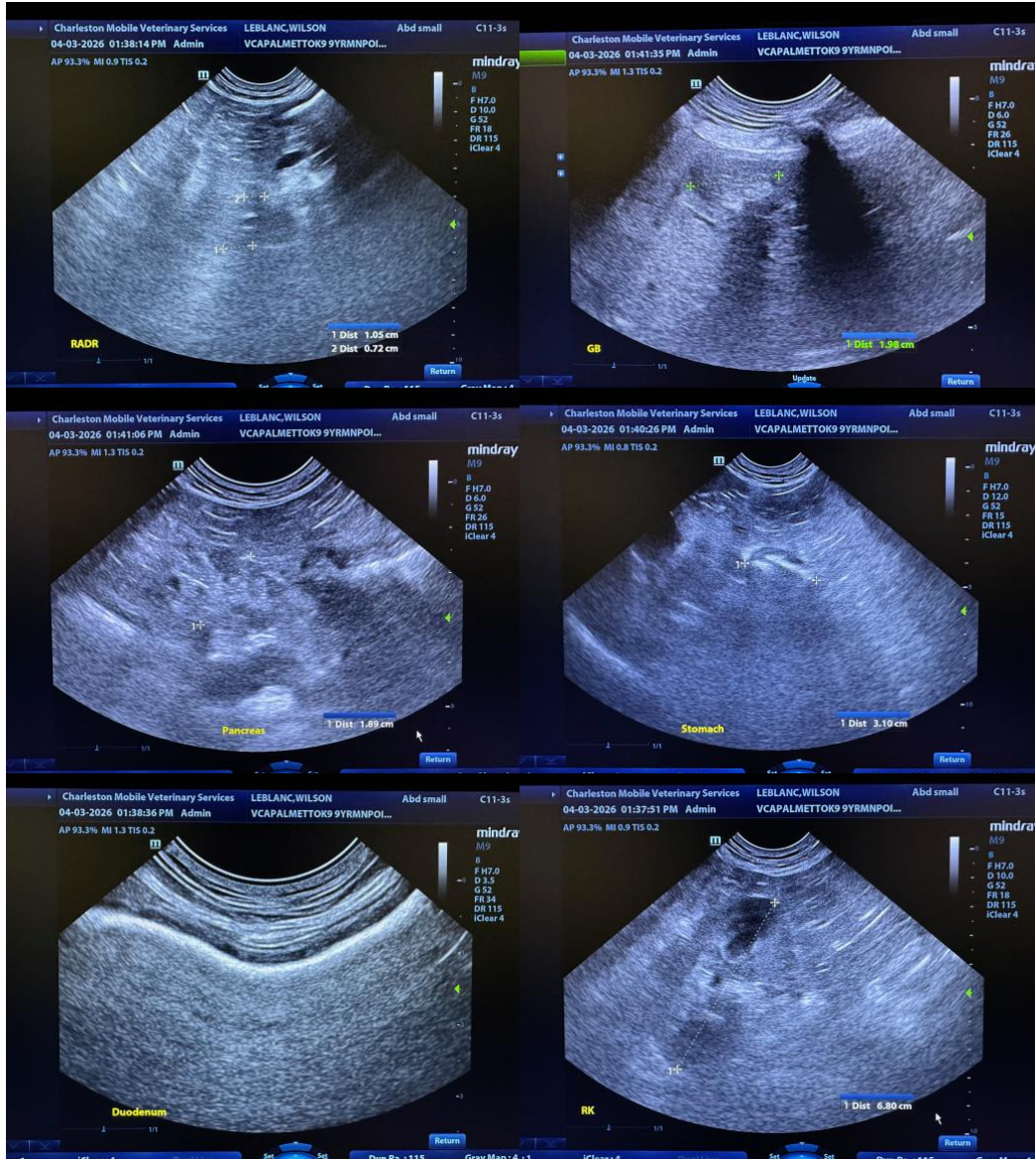
VCA Palmetto

INVOICE

22815

DATE

4-3-26





PATIENT

Wilson LeBlanc

SPECIES

Canine

BREED

Pointer

SEX

Male Neutered

AGE

7/21/2016

WEIGHT

33 kg

INTERPRETED BY

Andrea Nicastrò DVM
 Diplomate ACVIM
 (Sm Animal Internal Med)

IMAGING PERFORMED BY

Andrea Nicastrò DVM
 Diplomate ACVIM
 (Sm Animal Internal Med)

HOSPITAL NAME

Amber Leavis

REFERRING VET

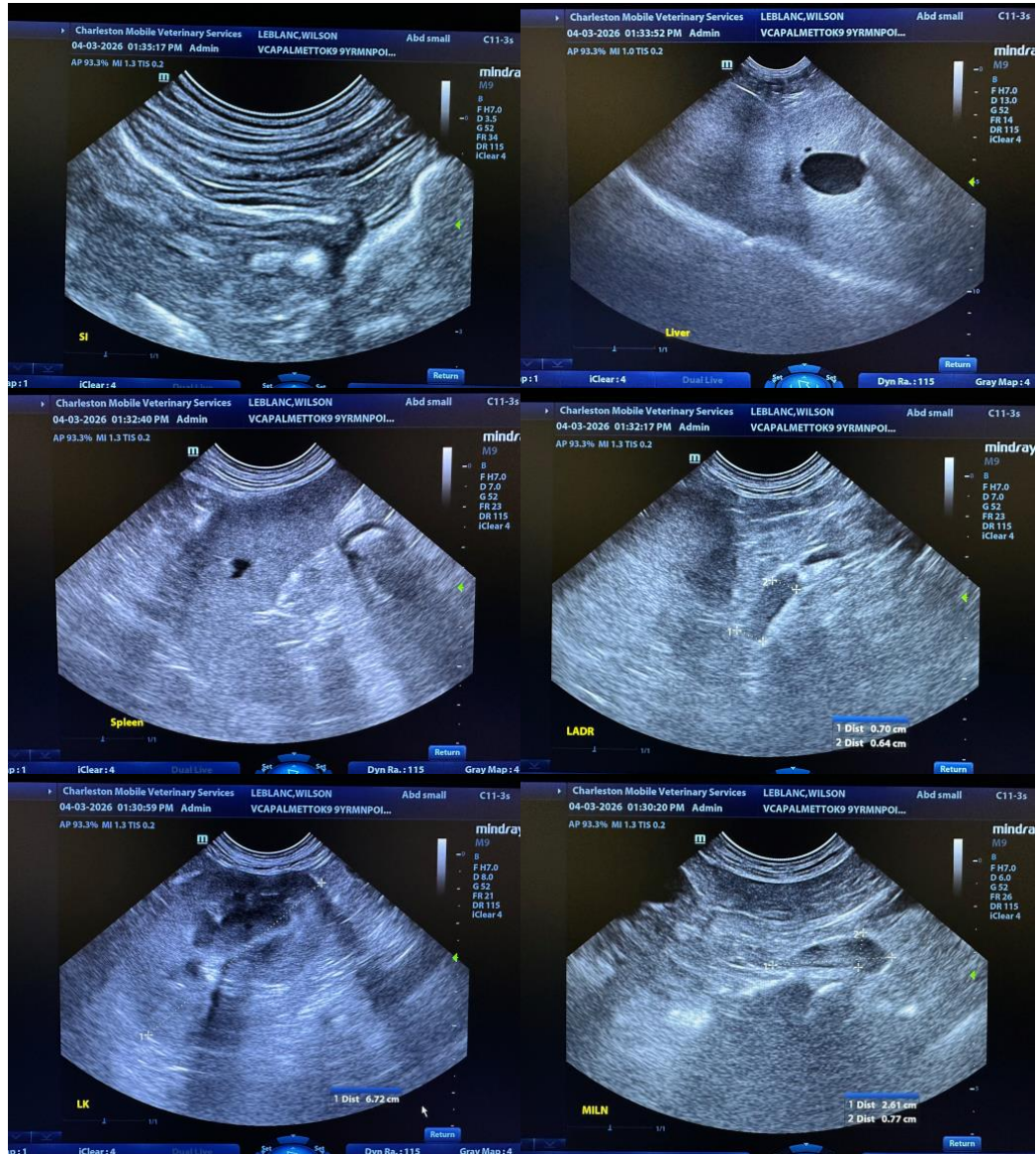
VCA Palmetto

INVOICE

22815

DATE

4-3-26





PATIENT

Wilson LeBlanc

SPECIES

Canine

BREED

Pointer

SEX

Male Neutered

AGE

7/21/2016

WEIGHT

33 kg

INTERPRETED BY

Andrea Nicastrò DVM
 Diplomate ACVIM
 (Sm Animal Internal Med)

IMAGING PERFORMED BY

Andrea Nicastrò DVM
 Diplomate ACVIM
 (Sm Animal Internal Med)

HOSPITAL NAME

Amber Leavis

REFERRING VET

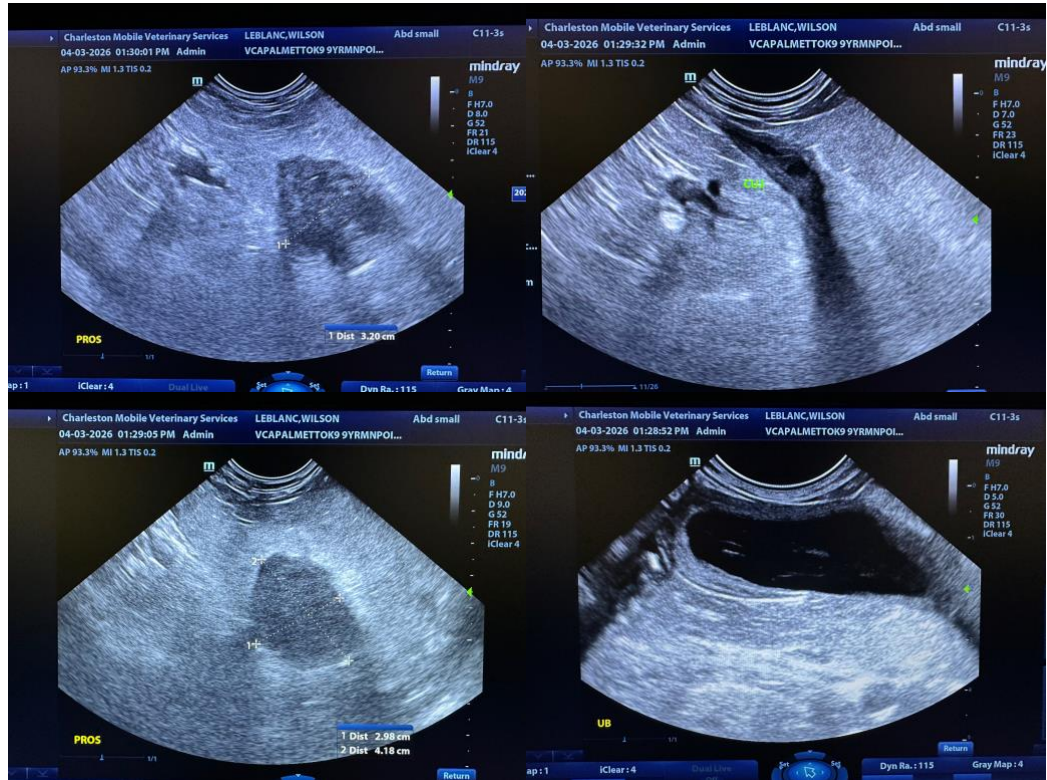
VCA Palmetto

INVOICE

22815

DATE

4-3-26



The information and recommendations provided are based on the images presented by the referring veterinarian/sonographer. No evaluation can be communicated regarding pathology that was not visible in the image/video clips provided.

Thank you for this referral. If the clinical or image interpretation does not parallel your findings or if I can be of any further assistance, please contact me.

Andrea Nicastrò, MPH, DVM, Diplomate DACVIM (Small Animal Internal Medicine)
info@SonoPath.com